


Research Article

Hepatoprotective Effects of Dawa-Ul-Kurkum, a Unani Polyherbal Preparation and the Possible Mechanisms in Experimental Model of Ethanol Induced Liver Damage in Rats

Mohd Rafi Reshi¹, Kavita Gulati², Maaz Naqvi¹, Nafaa Hasan¹, and Arunabha Ray^{1,*}

Abstract

Objective: Hepatotoxicity is commonly associated with necrosis, an increase in oxidative stress markers such as Nitrates and Nitrites (NOx) assay, Malondialdehyde levels, reduced glutathione (GSH) levels depletion, and increased liver markers.

Methods: In rats, liver toxicity was created by giving them a daily dose of ethanol, which caused hepatic derangement and an increase in various liver markers when compared to a control group. Different markers of liver damage were used to examine the effects of pharmacological treatments. Hydropic degeneration, fatty changes and hepatocellular necrosis is seen were also found on histopathological investigation in some locations.

Results: Both Dawa-ul-Kurkum and Hydro-alcoholic extract treatment revealed hepatoprotective effects that were comparable to those seen following normal medication treatment. When compared to controls, ethanol induced liver damage was associated with higher levels of Malondialdehyde levels and Nitrates and Nitrites (NOx) assay, but lower levels of reduced glutathione (GSH) levels. Different degrees of attenuation in various oxidative stress markers were elicited by Dawa-ul-Kurkum and Hydro-alcoholic treatments.

Conclusion: It finds that both treatment Dawa-Ul-Kurkum and its extract were helpful in preventing ethanol induced liver damage in rats, as they greatly reduced hepatotoxic damage markers.

Keywords: Hepatotoxicity, ethanol, Dawa-Ul-Kurkum, Histopathology

Introduction

The liver is an important organ that is involved in metabolism, storage, secretion, and detoxification. Chronic alcohol misuse can cause hepatotoxicity, putting the liver's normal function in jeopardy. Hepatotoxicity caused by ethanol is primarily caused by toxic byproducts of its metabolism, which cause oxidative stress [1]. Alcohol is a psychoactive chemical that has been linked to a variety of health concerns around the world [2]. Oxidative stress is one of the key mechanisms of ethanol-induced hepatotoxicity. Alcohol dehydrogenase converts ethanol to acetaldehyde, which is then oxidized to acetate by acetaldehyde dehydrogenase [3-6]. When ethanol is taken in excess, it is converted mostly to acetaldehyde by the enzyme cytochrome P450 (CYP2E1), which is implicated in the production of reactive oxygen species (ROS) [7-9]. As a result, oxidative stress is caused by an increase in ROS combined with a reduction in antioxidant capability. Recent research suggests that ethanol-induced oxidative stress plays a key role in the development and progression of alcoholic liver disease [10-12].

Affiliation:

¹Dept. of Pharmacology Hamdard Institute of Medical Sciences & Research, Jamia Hamdard University Delhi, New Delhi, India

²Dept. of Pharmacology, Vallabhbhai Patel Chest Institute, University of Delhi, New Delhi, India

***Corresponding author:** Arunabha Ray, Dept. of Pharmacology Hamdard Institute of Medical Sciences & Research, Jamia Hamdard University Delhi, New Delhi, India.

Citation: Mohd Rafi Reshi, Kavita Gulati, Maaz Naqvi, Nafaa Hasan and Arunabha Ray. Hepatoprotective Effects of Dawa-Ul-Kurkum, a Unani Polyherbal Preparation and the Possible Mechanisms in Experimental Model of Ethanol Induced Liver Damage in Rats. Journal of Pharmacy and Pharmacology Research 6 (2022): 122-130.

Received: August 13, 2022

Accepted: August 24, 2022

Published: August 30, 2022

Even today, there are no effective medications to slow or stop the advancement of alcoholic liver disease; consequently, new therapies are needed to stop the illness from progressing. Because of their antioxidant capacity and low side effects, medicinal plants and their active phytochemicals have piqued researchers' interest as potential medicines against alcoholic liver injury. The usage of medicinal plants has grown tremendously in popularity in recent decades; nevertheless, there is currently little scientific evidence to support its use as a cure or preventative for many diseases [13]. In the recent decade, complementary and alternative medicine approaches that use medicinal plants for sickness prevention and treatment have become increasingly popular. The application of these polyherbal medications in a variety of complex pathophysiological circumstances has also been proven by the application of modern medical technology to traditional medicine. In the past, a wide variety of medicinal herbs were used for immunomodulation and hepatoprotection, and their effects must now be verified using modern scientific methods. Dawa-ul-Kurkum, a polyherbal Unani formulation, is useful in situations of liver dysfunction, anorexia, ascites, and abdominal pain. This polyherbal is composed of Sunbul-ut-Teeb, Mur Makki, Saleekha, Qust, Shagufa-e-Izkhair, Darcheeni, Zafran, with Sharab-e-musallas and Qand Safaid [14]. Our goal of this study is to determine whether Dawa-ul-Kurkum has hepatoprotective benefits in ethanol induced liver damage in rats, as well as the mechanisms behind these effects.

Methods

Drugs and Chemicals

The drug and chemicals are taken from different suppliers like Dawa-UI- Kurkum provided by Central Research Institute of Unani Medicine, Hyderabad, Silymarin were purchased from Sigma and other chemicals were taken from SRL, New Delhi. Biochemical kits were purchased from ERBA.

Animals

The study employed either a male or female Wistar strain. Animals were seized from the Central Animal House Facility, Hamdard University and kept in a controlled environment. They were provided with unlimited food and drink. Animals were cared for according to CPCSEA criteria for animal usage, which were approved by the Institutional Animal Ethics Committee (IAEC) protocol number 1768 (Registration number 173/GO/ReBi/S/2000/CPCSEA).

The Investigational Drug

Dawa-ul-Kurkum, was provided by Central Research Institute of Unani Medicine (CRIUM), Ministry of AYUSH, Govt. of India with a batch no. 3-1/2018-19/CRIUM. This preparation is composed of Sunbul-ut-Teeb, Mur Makki,

Saleekha, Qust, Shagufa-e-Izkhair, Darcheeni, Zafran with Sharab-e-musallas and Qand Safaid QS [15]. The formulation is well documented in standard Unani literature and is certified to have been prepared as per traditional classical Unani text by CRIUM. Dawa-ul-Kurkum is a semi-solid preparation created with the ingredients listed below in the formulation [Table 1].

HPTLC of alcoholic extract of Dawa-UI-kurkum

Dawa-UI-Kurkum an important polyherbal formulations used for unani medicine. Standardization was carried out by Densitogram of alcoholic extract of Dawa-ul-kurkum at UV 366nm and UV 254nm [Table 2, 3 and Figure 1].

Table 1: Formulation Composition

S.No	Name	Botanical/sci. name	Qty	Part
1.	Sumbul-ut-tib	<i>Nordostachys jatamansi</i> DC. Syn. <i>Valeriana jatamansi</i>	1 Part	Dried Rhizomes
2.	Murmakki	<i>Commiphora myrrha</i> (Nees) Engl.	1 Part	Gum resin
3.	Saleekha	<i>Cinnamomum cassia</i> Blume	1 Part	Bark
4.	Qust	<i>Saussurea lappa</i> C.B. Clarke	1 Part	Dried roots
5.	Shagofa Izkher	<i>Cymbopogon jwarancusa</i> Schult Syn. <i>Andropogon jwarancusa</i> Jones	1 Part	Flower
6.	Darchini	<i>Cinnamomum zeylanicum</i> Blume	1 Part	Bark
7.	Zafran	<i>Crocus sativus</i> Linn.	1 Part	Style and stigma
8.	Sharab Musallas	-	Q.S	-
9.	Asal OR Qand Safaid	-	Q.S	-

Table 2: Peak list of alcoholic extract of Dawa-ul-kurkum at UV 366nm

Peak no	Y-Pos	Area	Area %	Height	Rf value
1	9.7	1731.46	84.02	747.93	0.01
2	24.2	12.96	0.63	10.16	0.21
3	30.4	56.38	2.74	31.68	0.29
4	44.7	19.06	0.93	8.98	0.49
5	79.0	240.80	11.69	86.68	0.96

Table 3: Peak list of alcoholic extract of Dawa-ul-kurkum at UV 254nm

Peak no	Y-Pos	Area	Area %	Height	Rf value
1	9.8	930.19	39.85	519.16	0.01
2	14.3	137.38	5.89	116.47	0.07
3	34.5	925.77	39.66	370.07	0.35
4	72.7	94.11	4.03	29.85	0.87
5	79.6	246.78	10.57	132.46	0.97

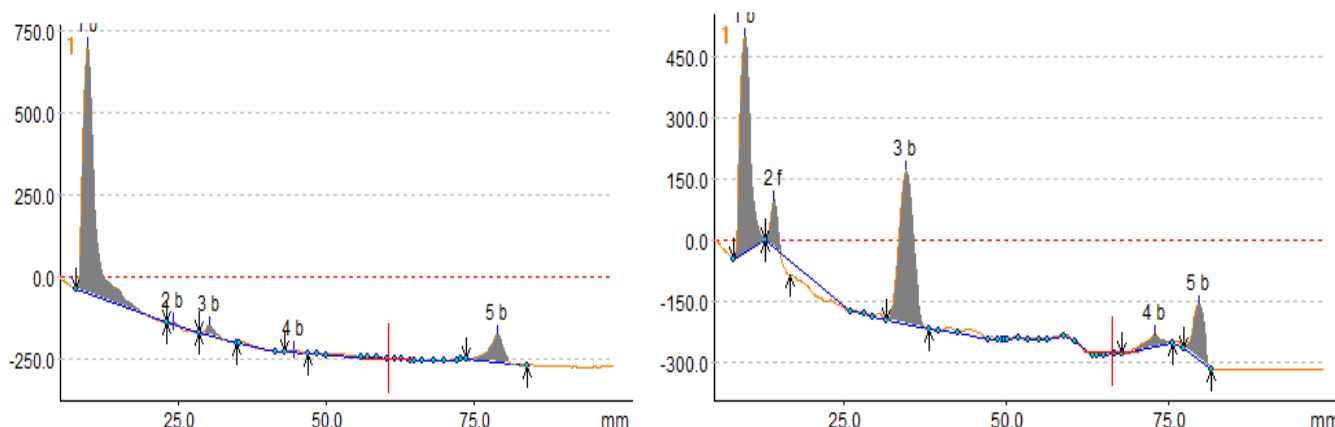


Figure 1: Densitogram of alcoholic extract of Dawa-ul-kurkum at UV 366nm and UV 254nm

Experimental Procedure (Ethanol induced liver damage in rats)

In this model, the animals were fed on standard rat chow, provided water ad libitum, and randomly divided into 7 groups of 5 rats each. Group I served as control and each rat was given an additional 2 ml/100 gm/day distilled water. The experimental Group II was given 2 ml (0.5 g)/100 gm body weight per day of 30% v/v of aqueous solution of ethanol for 6 weeks. Group-III positive control given silymarin at a dose of 50 mg/kg p.o., Group-IV and V given the Dawa-ul-Kurkum as per Unani specifications (250 and 500mg/kg, p.o.); Group-VI and VII given the HA extract of Dawa-ul-Kurkum as per Unani specifications (500 and 1000mg/kg, p.o.). After 6th week, blood samples were collected from all animals by cardiac puncturing under mild anesthesia, after that animals have been sacrificed and liver tissues were collected. The blood samples analyzed for biochemical markers of hepatic injury and tissue samples were subjected for histopathological studies and estimation of oxidative stress parameters [1].

Biochemical Estimations

Serum alanine aminotransferase (ALT), serum aspartate aminotransferase (AST) and serum alkaline phosphatase (ALP) were estimated by Kinetic method of International Federation of Clinical Chemistry (IFCC), serum bilirubin and total protein were estimated by End Point assay as per the instruction of the Kit Manufacture's manual.

Estimation of MDA levels

Malondialdehyde (MDA) is widely used as oxidative stress biomarker in biomedical research. Lipid peroxidation is measured spectrophotometrically as 2-thiobarbituric acid-reactive substance (TBARS) in supernatant of liver homogenate. 0.1 ml of supernatant was mixed with 0.2 ml of sodium dodecyl sulfate (8.1 %), 1.5 ml of 20 % acetic acid and 1.5 ml of 2-thiobarbituric acid (0.8 %). The reaction mixture was finally made up to 4.0 ml with distilled water.

After vortexing, samples were incubated for 1 h in 95° C and after cooling with tap water; 1.0 ml of distilled water and 5.0 ml of mixture of butanol–pyridine 15:1 (v/v) were added. The mixture was shaken for 10 min. and then centrifuged at 4000 rpm for 10 min. Then Butanol–pyridine layer was taken and measured spectrophotometrically at 532 nm. TBARS values are expressed as MDA equivalents. 1, 1, 3, 3-tetramethoxypropane (TMP) was used as the standard [16].

Assay of reduced glutathione (GSH) levels

Glutathione (GSH) levels were estimated by the method of Ellman [17]. This assay is based on the enzymatic recycling procedure in which glutathione was sequentially oxidized by the DTNB and reduced by NADPH in the presence of glutathione reductase. For assay, an equal quantity of sample was mixed with 10% trichloroacetic acid and centrifuged to separate the proteins. To 0.1 ml of this supernatant, 2 ml of phosphate buffer (pH 8.4), 0.5 ml of 5'-dithiobis (2-nitrobenzoic acid) and 0.4 ml of double distilled water was added. The mixture was vortexed and absorbance was read at 412 nm within 15 min. The concentration of 2-nitro-5-benzoic acid formation was measured and reduced glutathione is expressed as $\mu\text{mol}/\text{mg}$ protein.

Nitrates and Nitrites (NOx) assay

NOx concentrations were determined by using the Griess reaction described by Tracey et al. 50 μl of supernatant, 20 μl of 310 mM phosphate buffer (pH 7.5) and 10 μl each of 0.86 mM NADPH, 0.11 mM flavin adenine dinucleotide (FAD) and 10 μl Nitrate reductase (1 U/ml) in individual wells of a 96-well plate. Plate was thereafter incubated for 1 h at room temperature in the dark. 200 μl of Griess reagent [1:1 mixture of 1% sulfanilamide (1% solution with 5% orthophosphoric acid) and 0.1% N(1-naphthyl) ethylenediamine (NEDA) (1% solution with distilled water)] was added to each well and the plate was incubated for an additional 10 min at room temperature. Absorbance was measured at 540 nm using a microplate reader. Total protein was estimated by method

of Lowry et al [18]. Concentration of total nitrate and nitrite (NOx) in liver homogenates was calculated from the standard curve and expressed as nM/mg protein.

Histopathological examination

All groups were subjected to histological examination. Microscopic examination was done by a qualified pathologist using hemotoxylin and eosin staining in a blinded fashion.

Statistical Analysis

The values were expressed as mean \pm standard error of the mean. One-way analysis of variance (ANOVA) followed by appropriate post hoc test (Tukey test) were used for analysis. $P < 0.05$ was considered as statistically significant.

Results

Effects of Dawa-UI-Kurkum and its hydro-alcoholic extract on body weight and liver weight in ethanol induced liver damage in rats

The mean body weight was measured in all groups at 1st day and last day of 6th week and liver weight was also measured on last day after various drug treatments. The results showed that dose of ethanol daily dose caused less increase in the body weight and change in the liver weight when compared to that control rats. Interestingly, treatment with Dawa-UI-Kurkum with two different doses (250 and 500 mg/kg), 50% hydro-alcoholic extract of two different doses (500 and 1000mg/kg) and silymarin blocked the effects of ethanol and resulted in increase in the body weight with no significant changes in the liver weight. The increase in body weight can be due to improvement in appetite which may have due to hepatoprotective effect of Dawa-UI-Kurkum. The results are shown in [Table 4].

Effects of Dawa-UI-Kurkum and its hydro-alcoholic extract on Liver Function test (LFT) in ethanol induced liver damage in rats

In experimental control group, ethanol given 6weeks resulted in significant increase in serum levels of SGOT

($p < 0.05$), ALP ($p > 0.05$), total bilirubin ($p > 0.05$), direct bilirubin ($p < 0.05$), non-significant increase in SGPT, and reduction in total protein as compared to normal control rats. This suggests that notable degree of hepatotoxicity and tissue injury in the rat liver and validated our model of ethanol induced liver damage. In Group 4 and 5, treatment with Dawa-UI-Kurkum at two different doses 250 and 500mg/kg for 6weeks significantly attenuated the effects of ethanol and reduced level of serum SGOT ($p < 0.05$ at 250 dose), SGPT, ALP, total bilirubin and direct bilirubin ($p < 0.05$ at both doses) and increased level of serum total protein as compared to that in Experimental control group. Similarly, in Group 6 and 7 treatment with two different doses of 50% hydro-alcoholic (500 and 1000mg/kg) produced hepatoprotective effect as it reduced significantly the levels of serum SGOT ($p < 0.01$ at 1000mg/kg dose), SGPT ($p < 0.05$ at both doses), ALP ($p < 0.05$ at 500mg/kg dose), total bilirubin ($p < 0.05$ at 1000 mg/kg dose) and direct bilirubin ($p < 0.05$ at both doses), significantly increased total protein ($p < 0.05$ at 500mg/kg dose) as compared to that in Experimental control. Pretreatment with silymarin also significant reduced the hepatotoxic effects of ethanol and reduced the levels of serum SGOT ($p < 0.05$), SGPT ($p < 0.005$), ALP ($p < 0.05$), Total bilirubin ($p < 0.005$), and direct bilirubin ($p < 0.005$) but non-significantly increase in total protein as compared to that in Experimental control. The results of Dawa-UI-Kurkum and its hydro-alcoholic extract are comparable to that of Silymarin. The results are shown in [Figure 2, 3 and table 5].

Effects of Dawa-UI-Kurkum and its hydro-alcoholic extract on oxidative stress parameters in ethanol induced liver damage

In experimental control group, ethanol given daily dose for 6 weekly resulted in increase in stable metabolites of nitric oxide (NOx) ($P < 0.05$) and MDA ($P < 0.05$) in supernatant of liver homogenates and significant reduction in GSH ($P < 0.05$) as compared to control rats. This suggests a notable degree of hepatotoxicity and tissue injury in the rat liver and corroborated

Table 4: Effects of Dawa-UI-Kurkum and its hydro-alcoholic extract on body and liver weight

Treatment	Initial body weight (g)	Final body weight (g)	% change in	Liver weight (g)	Liver index (%)
			body weight		
Control	223.2 \pm 2.059	263.8 \pm 14.68	15.39	9.646 \pm 0.937	3.656
Experimental control	271.4 \pm 15.24	279.6 \pm 16.18	2.93	10.20 \pm 0.557	3.648
Silymarin	264.4 \pm 10.32	272.0 \pm 10.07	2.79	9.306 \pm 0.829	3.421
DK 250	281.0 \pm 4.266	292.0 \pm 18.81	3.76	9.956 \pm 0.767	3.409
DK500	280.6 \pm 11.59	298.0 \pm 22.34	5.83	7.646 \pm 1.852	2.565
HA500	233.8 \pm 7.144	248.0 \pm 7.622	4.78	10.04 \pm 1.312	4.048
HA1000	290.0 \pm 9.418	296.8 \pm 7.605	2.29	9.096 \pm 0.638	3.064

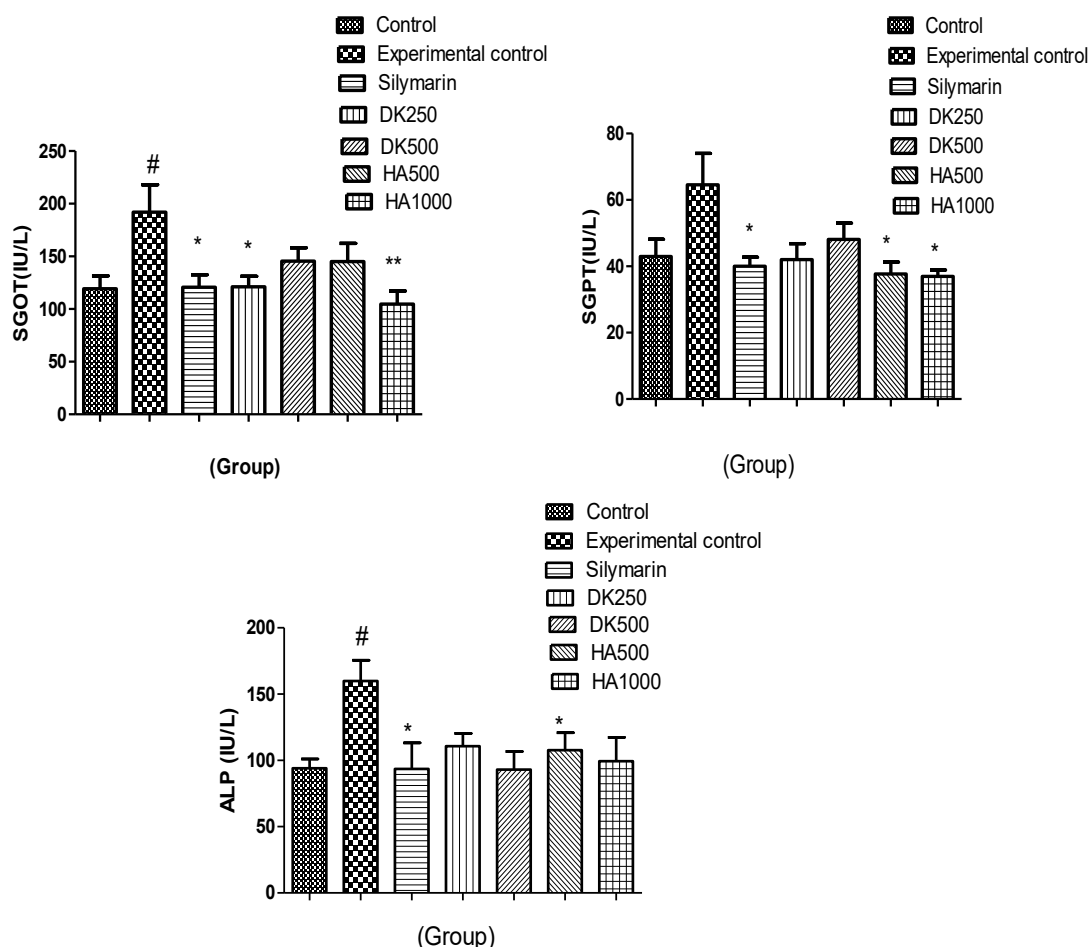


Figure 2: (a-c) Effects of Dawa-UI-Kurkum and its hydro-alcoholic extract on (a) SGOT (b) SGPT and (c) ALP. DK-Dawa-ul-kurkum; HA-Hydroalcoholic extract of DK

The values are expressed as mean \pm SEM; ($\#$ = $p < 0.05$ vs control group; $*$ = $p < 0.05$ and $**$ = 0.01 vs Experimental control. The data were analyzed using one-way ANOVA followed by Tukey's test.

to validate this model of hepatotoxicity. In Group 4 and 5, treatment with Dawa-UI-Kurkum at two different doses 250 and 500mg/kg for 6 weeks significantly attenuated the effects of ethanol and reduced level of homogenate supernatant NOx ($p < 0.05$ at 250 mg/kg doses), MDA ($p < 0.05$ at 250 mg/kg doses) and significantly increased GSH ($p < 0.05$ at 250mg/kg, dose) as compared to that in Experimental control group. Similarly, in Group 6 and 7 treatment with 50% hydro-alcoholic extract of two different doses (500 and 1000mg/kg) produced hepatoprotective effect as it significantly reduced the levels of NOx in homogenate supernatant ($p < 0.05$ at dose 500 mg/kg), MDA ($p < 0.05$ at 500 mg.kg doses) and significant increased GSH ($p < 0.05$ at dose 1000 mg/kg) as compared to that in Experimental control group. Pretreatment with silymarin also significantly reduced the hepatotoxic effects of ethanol and reduced the levels of NOx, MDA ($p > 0.05$) and increased GSH ($p < 0.05$) as compared to that in Experimental control group. The results of Dawa-UI-Kurkum and its hydro-alcoholic extract are comparable to that of Silymarin. The results are shown in [Figure 4].

Histopathological examination

Histopathological examination of the liver sections of vehicle treated (control) rats showed most of the hepatic parenchymal cells appeared normal. Few inflammatory cell infiltrate seen. In experimental control group, administration of ethanol daily 6weeks showed hydropic degeneration, fatty changes and hepatocellular necrosis is seen. Mild periportal inflammatory cell infiltrate and peri biliary fibrosis is also evident. This was suggestive of notable degree of hepatotoxicity and tissue injury in the rat liver and validated our model of hepatotoxicity. Silymarin treated group showed hydropic degeneration and Focal areas of inflammatory cell infiltrate are also seen. Mild peri biliary fibrosis is also seen. In Group IV and V, treatment with Dawa-UI-Kurkum at doses 250 and 500mg/kg respectively showed hepatocytes mostly appeared normal. Mild peri biliary fibrosis and inflammatory cell infiltrate is seen. In Group VI and VII treatment with 50% hydro-alcoholic extract of Dawa-UI-Kurkum (500 and 1000mg/kg) also showed hydropic degeneration and

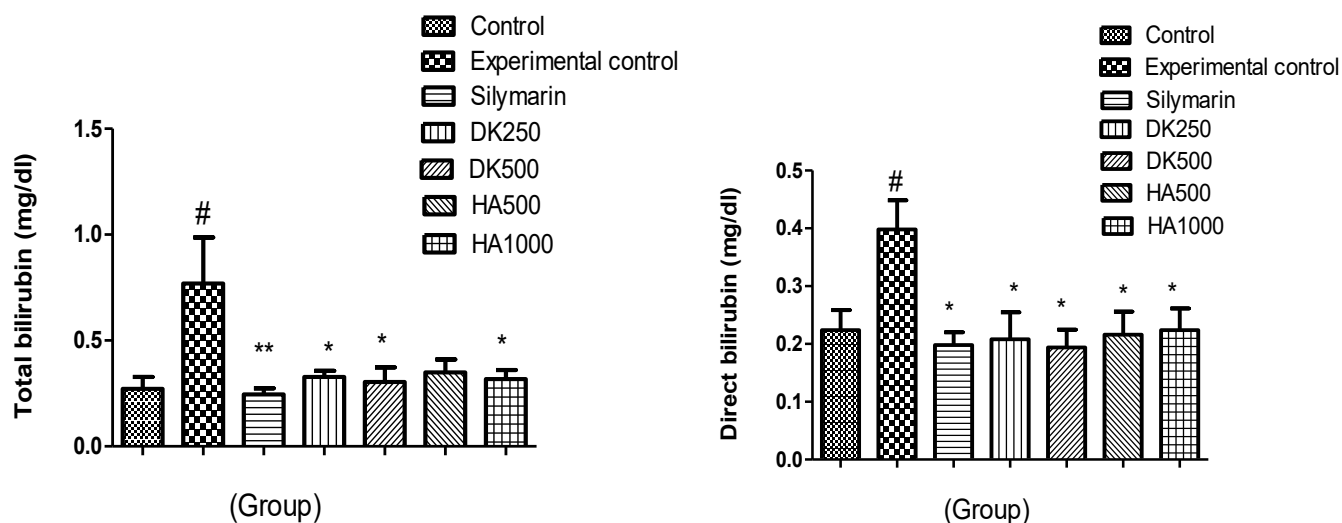


Figure 3: (a-b) Effects of Dawa-UI-Kurkum and its hydro-alcoholic extract on (a) Total bilirubin (b) Direct bilirubin

The values are expressed as mean \pm SEM; ([#]=p<0.05 vs control group; ^{*}=p<0.05 and ^{**}=0.01 vs Experimental control. The data were analyzed using one-way ANOVA followed by Tukey's test.

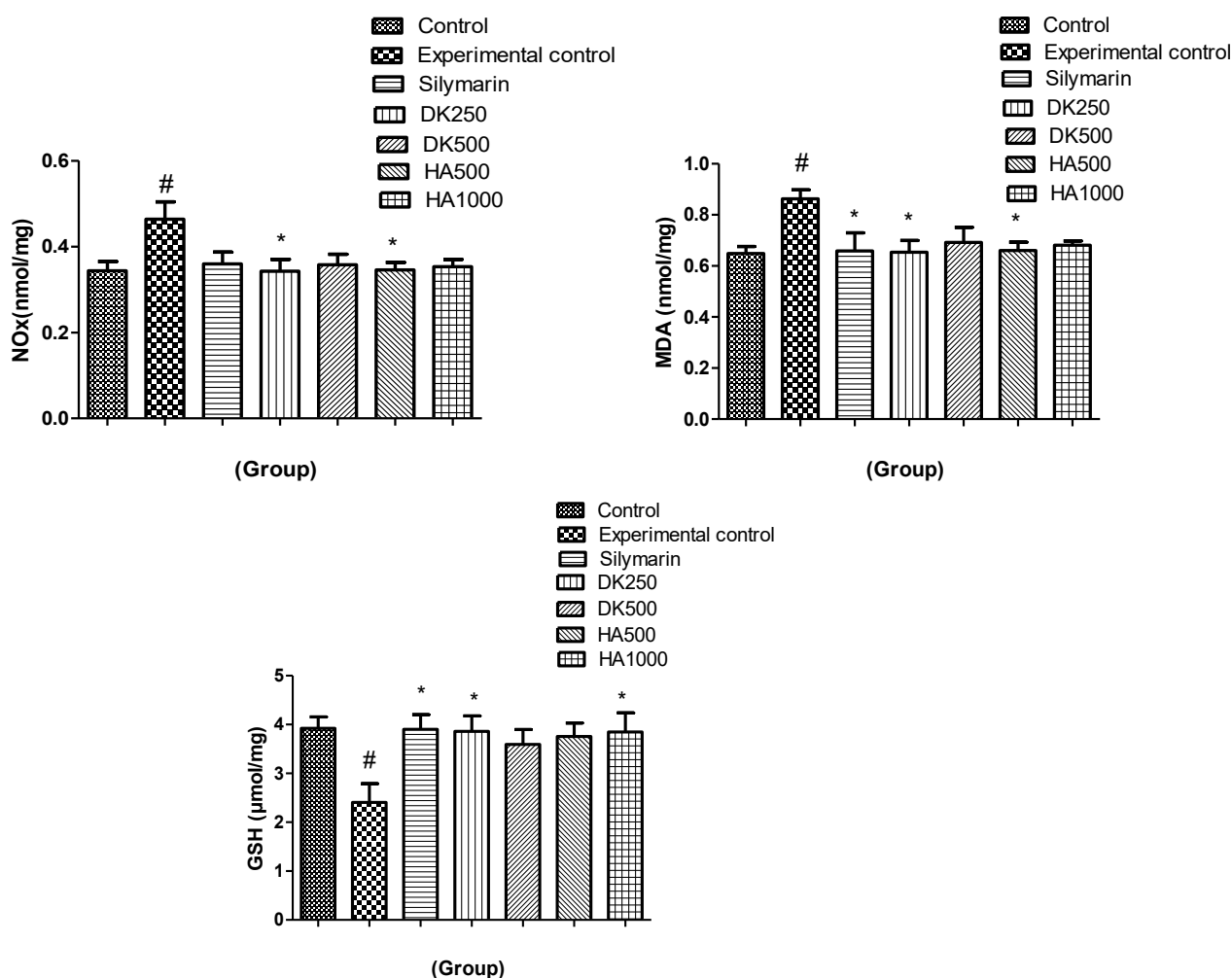


Figure 4: Effects of Dawa-UI-Kurkum and its hydro-alcoholic extract on (a) stable metabolites of nitric oxide (NOx), (b) MDA and (c) GSH

The values are expressed as mean \pm SEM; ([#]=p<0.05 vs control group; ^{*}=p<0.05 vs Experimental control. The data were analyzed using one-way ANOVA followed by Tukey's test.

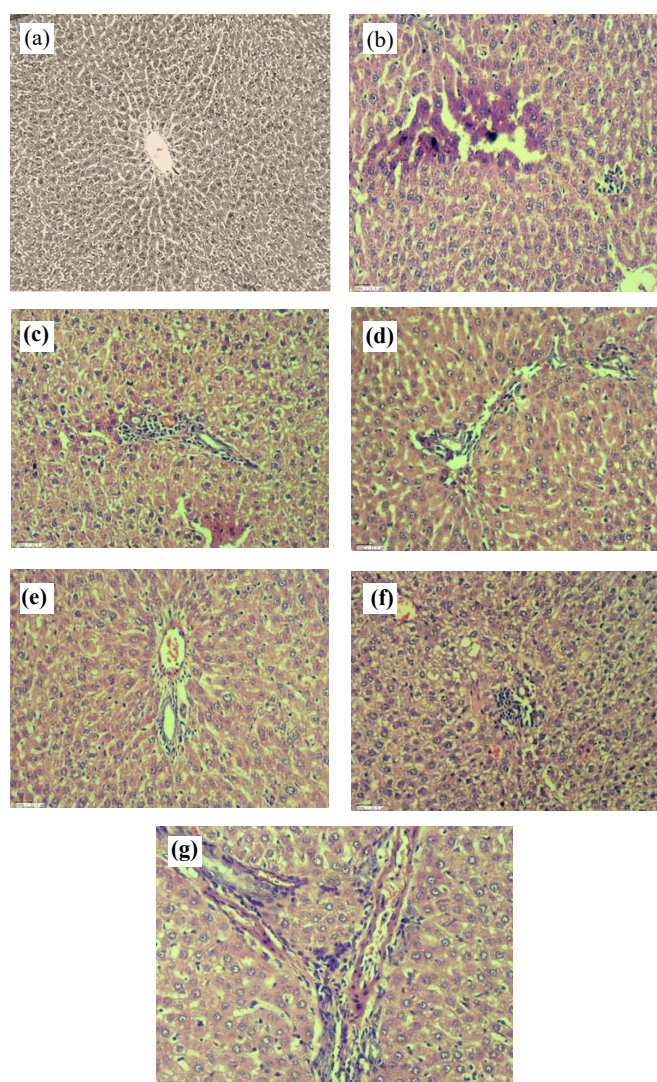


Figure 5: Histopathological picture of liver sections after various drug treatment in rats. a) Control; b) Experimental control; c) Silymarin; d) DK250; e) DK500; f) HA500; and g) HA1000. All groups except control group were treated with ethanol.

fatty change is seen in some part of the liver. Periportal inflammatory cell infiltrate is also seen. Peri biliary fibrosis is also seen. The results are shown in [Figure 5].

Discussion

In rats, chronic ethanol administration resulted in changes in body weight gain. Due to ethanol-induced liver injury, histological abnormalities in the liver tissue as well as biochemical changes in the blood and liver were found. When compared to the control groups, chronic oral administration of ethanol resulted in a significant reduction in mean body weight growth. Macdonald, Olusola, and Osaigbovo previously observed a reduced mean body weight gain in rats after continuous ethanol administration [19]. Energy loss related with ethanol metabolism via the

microsomal ethanol oxidizing mechanism could explain the lower increase in bodyweight (MEOS). The alcohol dehydrogenase and MEOS pathways are the primary routes for alcohol metabolism. Ethanol is mostly metabolized by the MEOS route in the presence of persistent alcohol intake. There is a change in energy usage and weight gain due to the induction of MEOS, which oxidizes ethanol without producing chemical energy [20].

The liver, which is the principal site of ethanol metabolism, is extremely vulnerable to the effects of persistent alcohol intake. The byproducts of ethanol metabolism (acetaldehyde and reactive oxygen species) promote lipid peroxidation in the cell membrane, which activates a cascade of inflammatory events that leads to hepatocyte necrosis and apoptosis [21].

Hepatic injury causes cell integrity to be compromised, resulting in cellular leakage and the release of cytosolic enzymes such as AST, ALT, and ALP into the bloodstream. Chronic ethanol treatment caused higher levels of serum indicators of hepatic damage in rats in the current investigation, indicating that ethanol may cause liver impairment. Chronic alcohol administration raised the levels of liver damage markers in the serum in rats, according to Rajakrishnan and Menon [22].

Estimating MDA levels in liver homogenate was used to quantify lipid peroxidation, which is a result of oxidative stress. Ethanol significantly elevated MDA levels in experimental control group. When compared to the control group who did not receive alcohol, this rise was highly significant. Highly reactive byproducts of ethanol metabolism could have accelerated lipid peroxidation. Macdonald et al. found an increase in lipid peroxidation caused by ethanol in a rat model [15]. In comparison experimental control group, both Dawa-Ul-Kurkum and hydro-alcoholic extract was efficient in avoiding lipid peroxidation by dramatically lowering the levels of MDA in the treatment group's liver homogenate. Lower levels of MDA in the treatment group's liver homogenate point to dawa-ul-kurkum role in reducing ethanol-induced lipid peroxidation, significant protection against lipid peroxidation.

The current findings demonstrated that when Dawa-Ul-Kurkum and 50% Hydro-alcoholic extract were combined with ethanol, the rise in serum SGOT, SGPT, ALP, total bilirubin, and direct bilirubin levels was significantly reduced. Furthermore, oxidative stress parameters in liver homogenates revealed that Unani polyherbal preparations and hydroalcoholic extracts protected against increased levels of reactive oxygen and nitrogen species in response to ethanol, as evidenced by lower MDA and NOx levels and significantly higher GSH levels. The DK showed the same effects as the HA extract on the oxidative stress scale. Most of the hepatic tissue seemed normal in both Dawa-

Ul-Kurkum and HA extract, although some peri biliary fibrosis was also seen, reaffirming the protective effect of this polyherbal formulation against ethanol-induced liver injury. On the other hand, Dawa-Ul-Kurkum and HA extract both exhibited a protective effect. These findings showed that Dawa-Ul-Kurkum and its HA formulation are both effective hepatoprotective medicines that help to avoid liver necrosis.

Conclusion

Ethanol induced was found to be potentially hepatotoxic to Wistar rats, as evidenced by changes in biochemical markers, oxidative stress, and histological examinations. The combination of Dawa-Ul-Kurkum and 50% hydro-alcoholic extract was found to be effective against ethanol induced liver damage in rats, significantly reducing hepatotoxic damage. Such translational studies using the reverse pharmacology approach could aid in the integration of traditional and modern medicinal concepts in the greater interest of drug development and rational use.

Acknowledgement

The research was supported by grants from the CCRUM, Ministry of AYUSH, New Delhi, which is duly acknowledged. The authors wish to thank CRIUM, Hyderabad for providing standardized Dawa-Ul-Kurkum preparations.

Authors Contributions

Mohd. Rafi Reshi was involved in the conduct of experiments, acquisition and analysis of data and drafting of the manuscript. Kavita Gulati was involved in conceptualization, planning and designing of the study. She also helped in the analysis of data and critical review of the manuscript. Maaz Naqvi and Nafaa Hassan also help during experiment work. Arunabha Ray was involved in planning of the study, interpretation of data and critical reviewing of manuscript. All authors approved the final version of the manuscript.

Conflict of interest

No conflict of interest

Funding

The research was supported by grants from the CCRUM, Ministry of AYUSH, New Delhi, India.

Ethical statement

Ethical approval was required as this study involve laboratory animals.

References

1. Ume SN, Serva PM, Aswathanarayana Setty JL. Ameliorative effect of flaxseed (*Linum usitatissimum*)

and its protein on ethanol-induced hepatotoxicity in Wistar rats, *J Food Biochem* 43 (2019): 1–11.

2. Livero FA, Acco A. Molecular basis of alcoholic fatty liver disease from incidence to treatment, *Hepatol Res* 46 (2016): 111-123.
3. Han KH, Hashimoto N, Fukushima M. Relationships among alcoholic liver disease, antioxidants, and antioxidant enzyme, *World J, Gastroenterol* 7 (2016): 37-49.
4. Xu Y, Leo MA, Lieber CS. Lycopene attenuates alcoholic apoptosis in HepG2 cells expressing CYP2E1. *Biochem. Biophys. Res, Commun* 308 (2003): 614-618.
5. Caro AA, Cederbaum AI. Oxidative stress, toxicology and pharmacology of CYP2E1, *Annu Rev Pharmacol, toxicol* 44 (2004): 27-42.
6. Brocardo PS, Gil-Mohapel J, Christie BR. The role of oxidative stress in fetal alcohol spectrum disorders. *Brain Res, Rev* 67 (2011): 209-225.
7. Beier JJ, McClain CJ. Mechanism and cell signaling in alcoholic liver diseases, *Biol Chem* 391 (2010): 1249-1264.
8. Cederbaum AI. Molecular mechanism of the microsomal mixed function oxidases and biological and pathological implications, *Redox Biol* 4 (2015): 60-73.
9. Abdelmegeed MA, Banerjee A, Jang S, Yoo SH, Yun JW, Gonzalez FJ, et al. CYP2E1 potentiates binge alcohol induced gut leakiness, steatohepatitis and apoptosis. *Free Radic, Biol Med* 65 (2013): 1238-1245.
10. Song Z, Deaciue I, Song M, Lee DY, Liu Y, Ji X, et al. Silymarin protects against acute ethanol induced hepatotoxicity in mice. *Alcohol, Clin Exp Res* 30 (2006): 407-413.
11. Semhil-Kumar KJ, Liao JW, Xiao JH, Gokila-Vani M, Wang SY. Hepatoprotective effect of lucidone against alcohol induced oxidative stress in human hepatic HepG2 cells through the up-regulation of HO-1/Nrf-2 antioxidant genes, *Toxicol Vitro* 26 (2012): 700-708.
12. Jin M, Ande A, Kumar A, Kumar S. Regulation of cytochrome P450 2E1 expression by ethanol: role of oxidative stress mediated p38/jnk/sp1 pathway, *Cell Death Dis* 4 (2013): 554.
13. Rabelo ACS, de-Pádua LK, Araújo CM, de-Araújo GR, de-Amorim MPH, Carneiro ACA, et al. Baccharis trimera protects against ethanol induced hepatotoxicity in vitro and in vivo, *J Ethnopharmacol* 215 (2018): 1–13.
14. Reshi MR, Gulati K, Rais-ur-Rahman, Akhtar Jamal, Ray A. Hepatoprotective Effects of Dawa-Ul-Kurkum, a Unani Polyherbal Preparation and the Possible Mechanisms in Experimental Model of D-Galactosamine Induced Liver Damage in Rats, *EC Pharmacol and Toxicol* 9 (2019): 948–960.

15. Reshi MR, Gulati K, Ray A. Modulation of immune mechanisms during hepatoprotective effects of Dawa-Ul-Kurkum, a Unani polyherbal preparation in experimental model of paracetamol induced liver damage in rats, Asian J of Pharmaceutical Research and Development 9 (2021): 23-30.
16. Reshi MR, Patyar RR, Patyar S. Comparative evaluation of manuka honey with honey in antitubercular drug-induced hepatotoxicity in rats, International J of Green Pharmacy 10 (2016): 117-121.
17. Reshi MR, Gulati K, Khan AA, Ray A. Effects of Dawa-ul-Kurkum, a Unanipolyherbal preparation, in anti-tubercular drug induced hepatotoxicity in rats and its possible mechanisms, International J of Herbal Medicine 8 (2020): 57-62.
18. Reshi MR, Gulati K, Khan AA, Ray A. Hepatoprotective Effects of Dawa-Ul-Kurkum, a Unani Polyherbal Preparation and the Possible Mechanisms in Experimental Model of Paracetamol Induced Liver Damage in Rats EC Pharmacol and Toxicol 9 (2021).
19. Macdonald IO, Olusola OJ, Osaigbovo UA. Effects of chronic ethanol administration on body weight, reduced glutathione (GSH), malondialdehyde (MDA) levels and glutathione-s-transferase activity (GST) in rats, New York Science J 3 (2010): 39-47.
20. Lieber CS. Perspectives: Do alcohol calories count. The American J. of Clinical Nutrition 54 (1991): 976-982.
21. Manzo-Avalos S, Saavedra-Molina A. Cellular and mitochondrial effects of alcohol consumption. International J of Environment Research and Public Health 7 (2010): 4281-4304.
22. Rajakrishnan V, Menon VP. Potential role of antioxidants during ethanol-induced changes in the fatty acid composition and arachidonic acid metabolites in male Wistar rats. Cell Biology and Toxicology 17 (2001): 11-22.