



## Research Article

# Alternative Treatment of NMSC Recurrent with NILS

Aferdita Stroka Koka<sup>1</sup>, Laver Stroka<sup>1</sup>, Blerina Cela<sup>2</sup>, Ronny Khadra<sup>3</sup>, Ali Guy<sup>4</sup>, Fjolla Hyseni<sup>5\*</sup>, Juna Musa<sup>6</sup>

<sup>1</sup>Stroka Clinic, Tirana, Albania

<sup>2</sup>Department of Anatomopathology, University Hospital Center "Mother Teresa", Tirana, Albania

<sup>3</sup> Access and Navigation specialist, Mayo Clinic Rochester, Minnesota, USA

<sup>4</sup>Clinical Assistant Professor, Department of Physical Medicine and Rehabilitation, New York University School of Medicine, NYU Medical Center, New York, USA

<sup>5</sup>Research Fellow, NYU Langone Health, New York, USA

<sup>6</sup>Postdoctoral Research Fellow, Department of Surgery, Mayo Clinic, Minnesota, USA

\***Corresponding Author:** Fjolla Hyseni Vokshi, Department of Urology, Research Fellow, NYU Langone Health, New York, USA

**Received:** 09 August 2021; **Accepted:** 26 August 2021; **Published:** 03 September 2021

**Citation:** Aferdita Stroka Koka, Laver Stroka, Blerina Cela, Ronny Khadra, Ali Guy, Fjolla Hyseni, Juna Musa. Alternative Treatment of NMSC Recurrent with NILS. Journal of Cancer Science and Clinical Therapeutics 5 (2021): 405-413.

### Abstract

Throughout 2018 in the "STROKA" clinic in Tirana, are presented for alternative treatment 28 patients with recurrent non melanoma skin cancer (NMSC) after standard treatment with surgery, radiotherapy or together for one or more lesions. All patients are diagnosed with Basal Cell Carcinoma and Squamous Cell Carcinoma, and are treated with NILS which contains extracts of some Albanian plants such as *Allium sativum*, *Juglans regia* and *Laurus nobilis*.

According to a certain methodology, the treatment of patients lasts from one to three months until the complete destruction of the tumor and the regeneration of the area below and around it. From the first session, the measure of the tumor was reduce and all the surface that has absorbed the Nils, was turn in a cruste. The crustes falls one after another until the tumor mass has end and the sound layer was reached. At this point, we stoped the sessions of treatment, because the process of regeneration starts. NILS solution is

applied topically and the number of sessions varied from 3-14 in our 28 patients. After complete recovery, all are advised for periodic check-ups after 1, 2, 3, 6, 12, 18, 24, 30 and 36 months, without limiting them further.

**Keywords:** NMSC; NILS

## 1. Introduction

Globally, the occurrence and mortality of cancer is on the rise--skin cancer is no exception [1]. Non-melanoma skin cancer (NMSC) is more common in men, and risk increases with age and prolonged exposure to sunshine at a young age [2]. Basal cell carcinoma (BCC) (80%) and squamous cell carcinomas (SCC) (16%) [3] are currently the two most common tumors in the world [4-7]. Compared to melanoma, these tumors, especially basiloma, often have better outcomes due to slower development and rare metastases [8]. At more advanced stages, SCC of the skin has a slightly higher chance of metastasizing near and far, while basiloma tends to grow and destroy the tissues around it causing aesthetic deformity [9, 10]. There are a variety of risk factors for SCC and BCC. Men with a family history of cancer are more likely to suffer from SCC, but this is not the case for BCC [11]. The five-year recurrence rate of NMSC is usually associated with smoking, immunosuppression, family history for SCC, and anatomical location on the cheeks, ears or nose [12]. Patients with tumors that have grown to the point of ulceration have significantly worse outcomes than others [13], so earlier detection improves the prognosis and reduces the cost of treatment [14]. Treatment options for BCC and SCC are numerous. The options include surgery, other destructive techniques such as cryotherapy or combination therapy of electrodesiccation and topical chemotherapy, but do not exclude other methods including alternative medicine. Some ingredients of plant and animal origin have attracted

scientific attention for use as agents for cancer prevention and treatment after both in vitro and in vivo animal studies [15].

## 2. Materials and Methods

The sample for this study consisted of 28 patients who had a recurrence of NMSC after their initial lesions were treated with surgery, radiotherapy, or both. After informed consent forms from the patients were obtained and the 28 patients were enrolled in this experimental study. The diagnoses were made by biopsy. The most common diagnosis was basal cell carcinoma (BCC) multiple facialis in 10.7% of participants, followed by squamous cell carcinoma (SCC) multiple facialis and SCC labi inferior (in 7.1% of cases, each). More than half of participants had BCC of the head and neck (53.6%), about one-third had SCC of head and neck (32.1%), 10.7% had both BCC and SCC on head and neck and the remaining 3.6% had nevoid BCC. In total 28 patients diagnosed with skin cancer, one-quarter of participants declared to have nevi, or atypical moles. Among those having nevi, 71% had them at the surface of the skin, 86% over the surface. In 43% of such patients nevi were colored and in 86% were not colored. Nevi appeared through the years in all cases and in 28.6% of patients they did not change, in 57.1% of cases they changed only slightly, and in 14.3% of cases the nevi did change significantly.

The lesion for which the participants have shown up in our clinic was ulcerated in 71.4% of cases and not ulcerated in 28.6% of cases. No patient (0%) had regional lymph nodes metastases. Of the 28 patients, about 61% of participants were males. The mean age of participants was  $65 \pm 15.4$  years (ranging from 32.7 to 87.3 years and more than half of patients (54%) were 61-80 years old at the time of the study. Mean body weight was 71.2 kg, mean height was 1.67

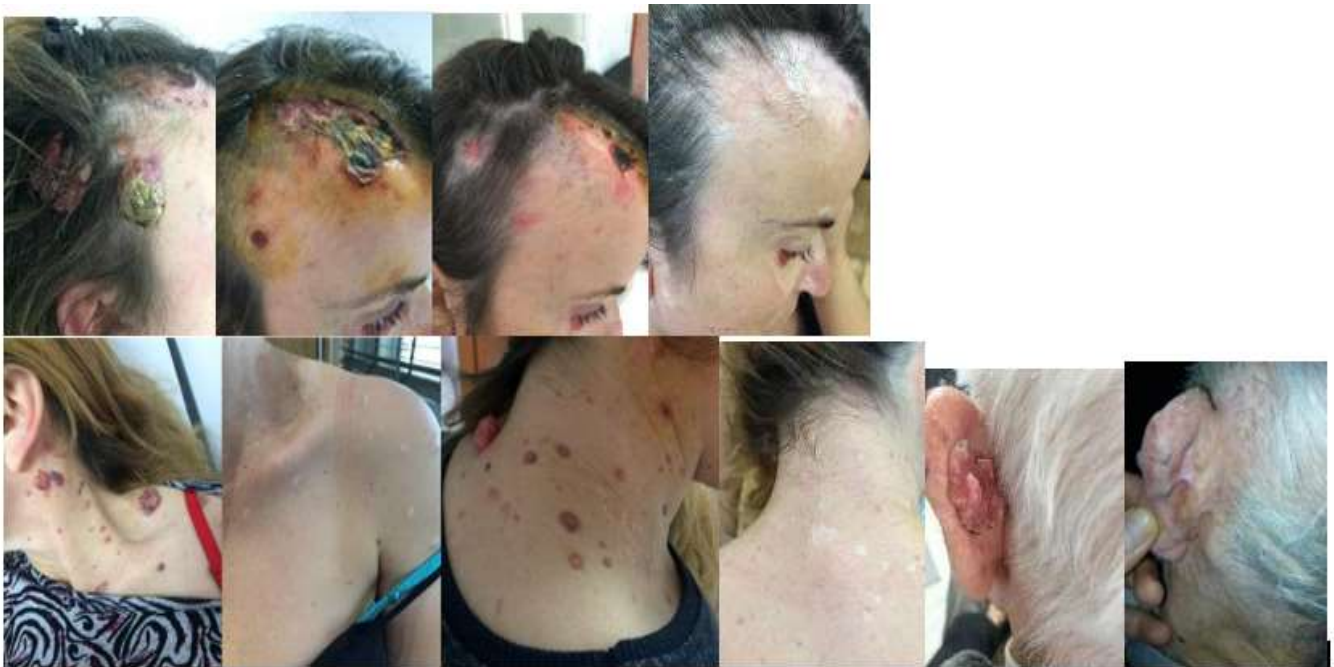meters and mean BMI index was 25.5 (with 46.4% being overweight). About two-thirds of study participants (64.3%) declared to have concomitant diseases, with hypertension being the most frequent one (in 83% of cases). One-third of participants had secondary education or less and about 57% were workers by profession. One-quarter of participants smoked, about 14% drank alcohol, about 86% consumed coffee, and none used drugs. In terms of diet, almost all consume dairy and meat products, eggs, fruits and vegetables. About half of participants had maroon hair (54%), brown eyes (57%) and about 36% had normal or good condition skin. Many of the participants had exposure to environmental risk factors. About 43% of participants had experienced sun burns in the past, 11% worked with chemicals, and a quarter had been exposed to frequent exams with radiation. More than one-fifth of participants (21.4%) had a positive family history.

This recurrence was treated with a local application of a solution of NILS. This is an extract of several plants originating from Albania, three of which are: *Allium sativum*, *Juglans regia* and *Laurus nobilis*. The treatment was performed locally by applying the solution (NILS) on the surface of the tumor mass. The treatment of patients lasted from one to three months—either until it succeeded or beyond the three months period of time, the treatment is unlikely to succeed. Success was determined by the complete

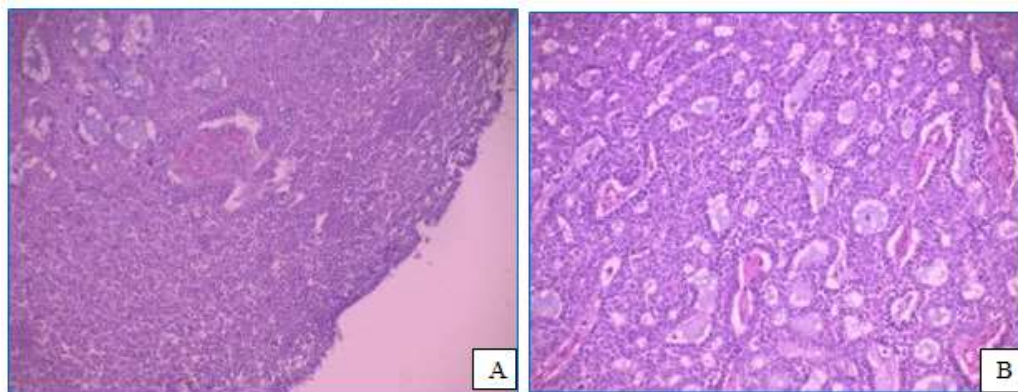
destruction of the tumor and, post-treatment, the regeneration of the surrounding area. The treatment was performed once a day and depending on the size of the lesion could last 20 to 30 minutes initially, often shortening as the sessions progressed. As treatment with NILS led to crust formation and shedding of the area it was applied to, it was terminated after the mass had been shed to reveal healthy skin so that the process of regeneration could begin.

### 3. Results

In about three-quarters of cases, the disease first appeared 5 or more years ago (mean 11.7 years ago). All patients underwent at least one type of treatment in order to control their condition: surgery was the most common treatment (in about 68% of cases), followed by radiotherapy alone (21%) and a combination of surgery and therapy (11%). Interestingly, after standard treatment, the lesion reoccurred in about 89% of patients and the lesions never completely healed in the remaining 11% of patients. After treatment in our clinic, the lesion(s) were completely healed in 89.3% of cases and in 7.1% of cases the lesions had closed down but it reappeared later on (recidivism). The most common duration of treatment for achieving complete healing of the lesion(s) involved 6 treatment sessions (in 32% of cases), followed by 5 sessions (in 20% of cases), and 4 and 3 sessions (12% of cases, each).

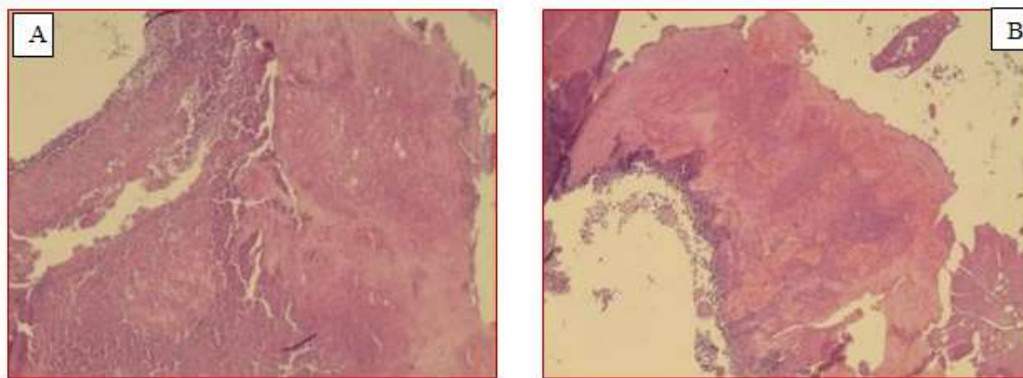


**Figure 1:** The case before, during and after the treatment.

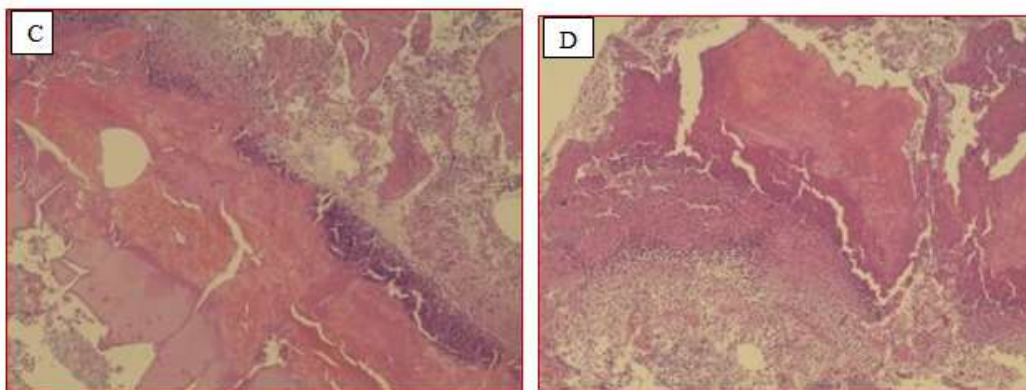


**Figure 2:** a and b, basophilic proliferation and peripheral palisading, together with myxoid stromal changes, characteristics of basal cell carcinoma (insert in a, the entire specimen examined).





**Figure 3:** A, B: depicted are the necrotic inflammatory changes of the lesion after the local treatment.



**Figure 4:** C, D: no vital residual tumor is present. Necrosis and inflammation is noted in all the layers of the specimen.

#### 4. Discussion

Skin cancer is a global problem common in the last four decades, especially in areas near the equator, but still without a global solution [16]. Significant causes include environmental pollution and sun exposure without proper skin care [19]. Across the globe, the role of ultraviolet radiation [24, 25] and radiation as a whole varies based on the geographical location: the seasons, hours of sunlight, altitude above sea level, and frequency of cloud cover [26]. Additionally, nicotine and nitrosamines are two important carcinogens released during smoking [27]. The role of

cellular processes [28] and genetic processes [29] play an important role in the growth of cancer. BCC is the most common tumor that develops on the skin in the most exposed parts to unprotected sun with less propensity for metastasis [20]. SCC often occurs in people who work mainly in nature, have a family history and smoke, drink alcohol [21] or have undergone immunosuppressive therapy for various diseases [22, 23]. The application of non-invasive diagnostic techniques such as dermoscopy has limited unnecessary biopsies [17, 18].

A worrying problem remains the recurrence of skin cancer in the prior location or in other areas of the skin after surgical treatment, radiotherapy or other methods (cryotherapy, electrodespiration, chemotherapy etc.) [30]. Cryotherapy is not recommended for the treatment of recurrent SCC [31]. In contrast, immunoprevention—based on a functioning immune system’s ability to control tumor development—can be used [32]. After surgical removals of NMSC, the size of the circular surface beyond the operated tumor is correlated to recurrence of NMSC. The 5-year survival rate varies from 10% to 54% when the resection limit exceeds the wound edge by 5-10 mm [33]. Oxidative stress damages body cells and stimulates mutations [34]. As such, the inclusion of many plants, which have high antioxidant content, in the diet can have a preventive action through multiple mechanisms [35]. The universal family diet rich in yogurt, fruits, vegetables, meat, etc. compiled by us has a preventive effect on cancer and various diseases [36]. Compared to the standard treatments, the advantage of treatment with NILS include:

1. The lack of local or systemic side effects and toxicity that the drug can cause during and after the end of treatment.
2. Can be used to treat groups that are contraindicated to apply standard treatments such as surgery or radiotherapy due to age, chronic or acute diseases of vital organs such as liver disease, heart disease, kidney disease, etc.
3. Allows the participation of patients with special conditions such as pregnancy or breastfeeding as well as a range of ages from 9-99 years treated with NILS in our clinic.
4. For diseases such as xeroderma pigmentosum or nevroid basal cell carcinoma syndrome, we believe that

it is the best solution to avoid the repeated need for surgical interventions due to the lower recurrence rate with NILS.

5. Due to the technique of application of this treatment, the patient can perform treatments without detachment from daily activity.
6. Patients treated for NMSC during 43 years of experience have never been complicated by adenopathy during or after treatment if they were presents without concomitant adenopathy [37].

## 5. Conclusion

NMSC is a disease most commonly encountered in recent decades, especially in areas near the equator. The STROKA clinic has almost a century of experience in treating tumors with NILS herbal solution. This has successfully treated 89.3% of the patients with recurrent NMSC, significantly lower than that of current treatments. The nearby lymph nodes, the bone and the organs were not affected by tumor mass in the patients that were treated in our clinic.

## References

1. Freddie Bray, Jacques Ferlay, Isabelle Soerjomataram, et al. Global cancer statistics 2018: GLOBOCAN estimates of incidence and mortality worldwide for 36 cancers in 185 countries. *CA: A Cancer Journal for Clinicians* 68 (2018).
2. MNewlands C, R Currie, A Memon, et al. Non-melanoma skin cancer: United Kingdom National Multidisciplinary Guidelines . *J Laryngol Otol* 130 (2016): S125–S132.
3. Jacqueline Dinnes, Jonathan J Deeks, Naomi Chuchu, et al. Visual inspection and dermoscopy, alone or in combination, for diagnosing keratinocyte

- skin cancers in adults. *Cochrane Database Syst Rev* 2018 (2018): CD011901.
4. Christopher M Doran, Rod Ling, Joshua Byrnes, et al. Estimating the economic costs of skin cancer in New South Wales, Australia. *BMC Public Health* 15 (2015): 952.
  5. Karin A Vineretsky, Margaret R Karagas, Brock C Christensen, et al. Skin Cancer Risk Is Modified by KIR/HLA Interactions That Influence the Activation of Natural Killer Immune Cells. *Cancer Res* 76 (2016): 370-376.
  6. Upekha E Liyanage, Matthew H Law, Xikun Han, et al. Combined analysis of keratinocyte cancers identifies novel genome-wide loci. *Hum Mol Genet* 28 (2019): 3148-3160.
  7. Tomotaka Sobue, Tetsuhisa Kitamura, Norie Sawada, et al. Epidemiology of nonmelanoma skin cancer in Japan: Occupational type, lifestyle, and family history of cancer. *Cancer Science* 111 (2020).
  8. Jacqueline Dinnes, Jonathan J Deeks, Naomi Chuchu, et al. Visual inspection and dermoscopy, alone or in combination, for diagnosing keratinocyte skin cancers in adults. *Cochrane Database Syst Rev* 2018 (2018): CD011901.
  9. Lavinia Ferrante di Ruffano, Yemisi Takwoingi, Jacqueline Dinnes, et al. Computer-assisted diagnosis techniques (dermoscopy and spectroscopy-based) for diagnosing skin cancer in adults. *Cochrane Database Syst Rev* 2018 (2018): CD013186.
  10. Mihai Lupu, Constantin Caruntu, Maria Iris Popa, et al. Vascular patterns in basal cell carcinoma: Dermoscopic, confocal and histopathological perspectives. *Oncol Lett* 17 (2019): 4112-4125.
  11. Honglin Cai, Tomotaka Sobue, Tetsuhisa Kitamura, et al. Epidemiology of nonmelanoma skin cancer in Japan: Occupational type, lifestyle, and family history of cancer. *Cancer Sci* 111 (2020): 4257-4265.
  12. Tina Vajdi, Robert Eilers, Shang I Brian Jiang. Clinical Characteristics of Non-Melanoma Skin Cancers Recurring within 5 years after Mohs Micrographic Surgery: Single Institution Retrospective Chart Review. *J Clin Investig Dermatol* 5 (2017): 10.13188/2373-1044.1000036.
  13. Faruk Tas, Kayhan Erturk. Primary tumour ulceration in cutaneous melanoma: its role on TNM stages. *Japanese Journal of Clinical Oncology* (2020).
  14. Lavinia Ferrante di Ruffano, Jacqueline Dinnes, Naomi Chuchu, et al. Exfoliative cytology for diagnosing basal cell carcinoma and other skin cancers in adults. *Cochrane Database Syst Rev* 2018 (2018): CD013187.
  15. Jessy Moore, Michael Yousef, Evangelia Tsiani. Anticancer Effects of Rosemary (*Rosmarinus officinalis* L.) Extract and Rosemary Extract Polyphenols. *Nutrients* 8 (2016): 731.
  16. Global Burden of Disease Cancer Collaboration. Global, Regional, and National Cancer Incidence, Mortality, Years of Life Lost, Years Lived With Disability, and Disability-Adjusted Life-Years for 29 Cancer Groups, 1990 to 2017. A Systematic Analysis for the Global Burden of Disease Study. *JAMA Oncol* 5 (2019): 1749-1768.
  17. Verena Ahlgrimm-Siess, Martin Laimer, Harold S Rabinovitz, et al. Confocal Microscopy in Skin Cancer. *Curr Dermatol Rep* 7 (2018): 105-118.

18. Chuchu N, Dinnes J, Takwoingi Y, et al. Tele dermatology for diagnosing skin cancer in adults. *Cochrane Database of Systematic Reviews* (2018).
19. Mei Ming, Weinong Han, Baozhong Zhao, et al. Gupta and Yu-Ying He. SIRT6 Promotes COX-2 Expression and Acts as an Oncogene in Skin Cancer. *Cancer Res* 74 (2014): 5925-5933.
20. Hany Eldeeb, Craig Macmillan, Christine Elwell, et al. The Effect of the Surgical Margins on the Outcome of Patients with Head and Neck Squamous Cell Carcinoma: Single Institution Experience. *Cancer Biology & Medicine* 9 (2012).
21. Ravi Mehrotra, Yadav S. Oral squamous cell carcinoma: Etiology, pathogenesis and prognostic value of genomic alterations. *Indian Journal of Cancer* 43 (2006): 60-66
22. Frank I Scott, RonacMamtani, Colleen M Brensinger, et al. Risk of non-melanoma skin cancer in patients with a history of NMSC with the use of immunosuppressant and biologic agents in autoimmune disease. *JAMA Dermatol* 152 (2016): 164-172.
23. Artur Fahradyan, Anna C Howell, Erik M Wolfswinkel, et al. Updates on the Management of Non-Melanoma Skin Cancer (NMSC). *Healthcare (Basel)* 5 (2017): 82.
24. Edward V Maytin, Sanjay Anand, Margo Riha, et al. 5-Fluorouracil Enhances Protoporphyrin IX Accumulation and Lesion Clearance during Photodynamic Therapy of Actinic Keratoses: A Mechanism-Based Clinical Trial. *Clin Cancer Res* 24 (2018): 3026-3035.
25. Susana Puig, Corinne Granger, Aurora Garre, et al. Review of Clinical Evidence over 10 Years on Prevention and Treatment of a Film-Forming Medical Device Containing Photolyase in the Management of Field Cancerization in Actinic Keratosis. *Dermatol Ther (Heidelb)* 9 (2019): 259-270.
26. Sérgio Schalka, Denise Steiner, Flávia Naranjo Ravelli, et al. Brazilian Consensus on Photoprotection. *An Bras Dermatol* 89 (2014): 1-74.
27. Supriya Srinivasan, Tulasigeri Totiger, Chanjuan Shi, et al. Tobacco Carcinogen-Induced Production of GM-CSF Activates CREB to Promote Pancreatic Cancer. *Cancer Res* November 78 (2018): 6146-6158.
28. Damian A AlmironBonnin, Matthew C Havrda, Mark A Israel. Glioma Cell Secretion: A Driver of Tumor Progression and a Potential Therapeutic Target. *Cancer Res* 78 (2018): 6031-6039.
29. Nurbubu T Moldogazieva, Sergey V Lutsenko, Alexander A Terentiev. Reactive Oxygen and Nitrogen Species-Induced Protein Modifications: Implication in Carcinogenesis and Anticancer Therapy. *Cancer Res* 78 (2018) 6040-6047.
30. Linus TD Armstrong, Mark R Magnusson, Michelle PB Guppy. Risk factors for recurrence of facial basal cell carcinoma after surgical excision: A follow-up analysis. *Journal of Plastic, Reconstructive & Aesthetic Surgery* 70 (2017): 1738-1745.
31. Peter Foley-Author, Stephen Shumack, Michelle Goh, et al. Cryotherapy and electrodesiccation and curettage for cutaneous squamous cell carcinoma. *Cancer Council Australia* 20 (2019).
32. Altaf Mohammed, Robert H Shoemaker, Shizuko Sei. Cancer Immunoprevention: Challenges and Potential Opportunities for Use of Immune



- Checkpoint Inhibitors. *Cancer Prev Res (Phila)* 13 (2020): 897-900.
33. Artur Fahradyan, Anna C Howell, Erik M Wolfswinkel, et al. Updates on the Management of Non-Melanoma Skin Cancer (NMSC). *Healthcare (Basel)* 5 (2017): 82.
34. Noriko NODA, Hiro WAKASUGI. Cancer and Oxidative Stress. *JMAJ* 44 (2001): 535-539.
35. Hajime OHIGASHI. Chemoprevention with Dietary Plants: Promising Phytochemicals, Animal Model Studies and Possible Mechanisms of Action. *Japanese Journal of Complementary and Alternative Medicine* (2008): 19-26.
36. Laver M Stroka dhe, Aferdita L Stroka. Tirana, Trajtimi standart dhe alternativ i semundjeve. F 505 (2021).
37. Aferdita Stroka Koka, Laver Stroka. Treatment of Skin Cancer with Alternative Medicine Method. *JNT* (2019): 123-141.



This article is an open access article distributed under the terms and conditions of the [Creative Commons Attribution \(CC-BY\) license 4.0](https://creativecommons.org/licenses/by/4.0/)