
**Research Article**

## A Unique Case of Acute Renal Failure and Hepatocellular Injury Occurring in the Course of a Mild SARS-CoV-2 Infection

Serena Marinello<sup>1\*</sup>, Nicolò Presa<sup>1</sup>, Gianluca Cuva<sup>2</sup>, Maria Mazzitelli<sup>1</sup>, Marco Trevenzoli<sup>1</sup>, Lolita Sasset<sup>1</sup>, Claudia Mescoli<sup>3</sup>, Federico Nalesso<sup>2</sup>, Annamaria Cattelan<sup>1</sup>

### Abstract

SARS-CoV-2 has tropism and replicates not only in the respiratory tract but also in extrapulmonary organs, such as heart, kidney, and liver. Clinical reports indicate that kidney involvement is frequent and ranges from mild proteinuria to an advanced acute kidney injury (AKI). Similarly, abnormal liver function parameters are commonly found in patients with SARS-CoV-2 infection. We describe a recent and unique case of acute renal failure and hepatocellular injury occurring in the course of a mild SARS-CoV-2 infection. A 37-year-old woman presented at ER with a 5-day history of general asthenia, fever, vomiting, and decreased urine output. She reported a positive SARS-CoV-2 antigen test performed 4 days earlier and no other comorbidities. Initial laboratory findings revealed severe renal impairment (sCr 4.57 mg/dl), non-responsive to intravenous diuretic therapy, with a need to start renal replacement therapy (RRT). She presented also with concomitant liver injury (AST/ALT 875/1349 U/L) for which a liver's biopsy was performed, finding a morphological aspect suggestive of COVID-related microvascular damage. Further hematochemical and microbiological exams were performed to exclude infectious, metabolic, neoplastic, toxic, and autoimmune diseases, confirming the diagnosis of acute renal failure and hepatocellular injury triggered by SARS-COV-2 infection. Liver and kidney function gradually improved and RRT was stopped after three consecutive sessions. Follow-up showed complete recovery of liver and kidney function twenty-eight days after the onset of symptoms. The case illustrates the complex pathophysiology of COVID-19 that frequently may severely involve extrapulmonary organs, without giving respiratory symptoms, like in this patient.

### Introduction

Since the beginning of the pandemic, SARS-CoV-2 infection has been characterized by its highly tropism for the respiratory tract, even though (along the course of the pandemic) a multisystemic viral spread and effects on a tissue and cellular level have been demonstrated [1]. In the understanding the pathophysiology of COVID-19, endothelial dysfunction seems to play an important role, as the result of the expression on the endothelial cells of the receptors required for SARS-CoV-2 to entry into the cells, i.e., the angiotensin-converting enzyme 2 (ACE 2). In recent immunohistochemical studies, it has been showed that SARS-CoV-2 has tropism and replicates not only in all the bronchoalveolar system but also in extrapulmonary organs, such as heart, kidney, and liver [2]. Clinical reports indicate that kidney involvement is frequent and ranges from mild proteinuria to an advanced Acute Kidney Injury (AKI). Acute Kidney Injury (AKI) has been described

#### Affiliation:

<sup>1</sup>University Hospital of Padova Infectious Diseases Department, Italy

<sup>2</sup>University Hospital of Padova Nephrology Department, Italy

<sup>3</sup>University Hospital of Padova Pathological Anatomy Section

#### \*Corresponding Author

Serena Marinello, University Hospital of Padova Infectious Diseases Department, Italy.

**Citation:** Serena Marinello, Nicolò Presa, Gianluca Cuva, Maria Mazzitelli, Marco Trevenzoli, Claudi, Claudia Mescoli, Federico Nalesso, Annamaria Cattelan. A Unique Case of Acute Renal Failure and Hepatocellular Injury Occurring in the Course of a Mild SARS-CoV-2 Infection. Archives of Clinical and Medical Case Reports. 7 (2023): 324-327.

**Received:** April 26, 2023

**Accepted:** May 03, 2023

**Published:** July 28, 2023

in up to 34% COVID-19 inpatients and in 77% of those admitted in Intensive care Unit [3] especially in those with pre-existing chronic renal injury [4], but also in previously healthy patients. Preexisting renal disease is considered one of the prognostic factors for worse outcome, mortality and ICU admission. At the same time developing COVID-19 related AKI, the need for Renal Replacement Therapy (RRT), is associated with adverse outcome in COVID-19 [5].

Similarly, abnormal liver function parameters are commonly found in patients with SARS-CoV-2 infection with an incidence ranged from 14.8 to 53% [6]. It has been shown that higher incidence rates of increased liver enzymes are associated with severe COVID-19 evolution. In a large series of patients, elevated serum AST levels were observed in nearly 18% of patients with non-severe COVID-19 disease and in approximately 56% of patients with severe COVID-19 disease. Indeed, the presence of a pre-existing liver disease have been associated with high rates of hepatic decompensation, acute- on- chronic liver failure and a more severe COVID-19 course [7]. Here in, we present the clinical course of a patient who presented with AKI and liver injury during a mild COVID-19 illness.

## Case

A 37-year-old Slovakian woman presented to the Emergency Department with a 5-day history of general asthenia, fever, vomiting, abdominal pain and decreased urine output. She reported a positive SARS-CoV-2 antigen test performed 4 days earlier and no other comorbidities. She received two doses of the Pfizer COVID-19 vaccine eight months before hospital admission. She denied travel to foreign countries, tick bites, high-risk sexual behaviors, and taking unconventional drugs. She had been taking acetaminophen and NSAIDs at therapeutic dosage without symptomatic improvement for 4 days. On presentation, she was febrile to 38.1°C with a heart rate of 5, respiratory rate of 14, blood pressure of 90/130 mmHg, and saturating well on room air. Physical examination showed dehydration of skin and mucous membranes, no edema in both legs. Initial laboratory findings revealed renal impairment with serum creatinine (sCr) at 4.57 mg/dl, the estimated glomerular filtration rate (eGFR) 18 ml/min/1.73m<sup>2</sup> urine protein (3+), protein quantification 1g/L, urine occult blood (3+), and urine sediment of red blood cells > 100/HPF (high-power fields). AST/ALT 875/1349 U/L. Chest and abdominal x-rays were unremarkable.

She was then admitted to our Infectious Diseases Unit where intravenous diuretic therapy was promptly initiated, without obtaining any laboratory improvement. Urine output decreased to 500mL and 400mL per 24 hours on hospitalization days one and four respectively. Renal replacement therapy (RRT) was therefore introduced, for a total of three consecutive sessions. His urine output gradually

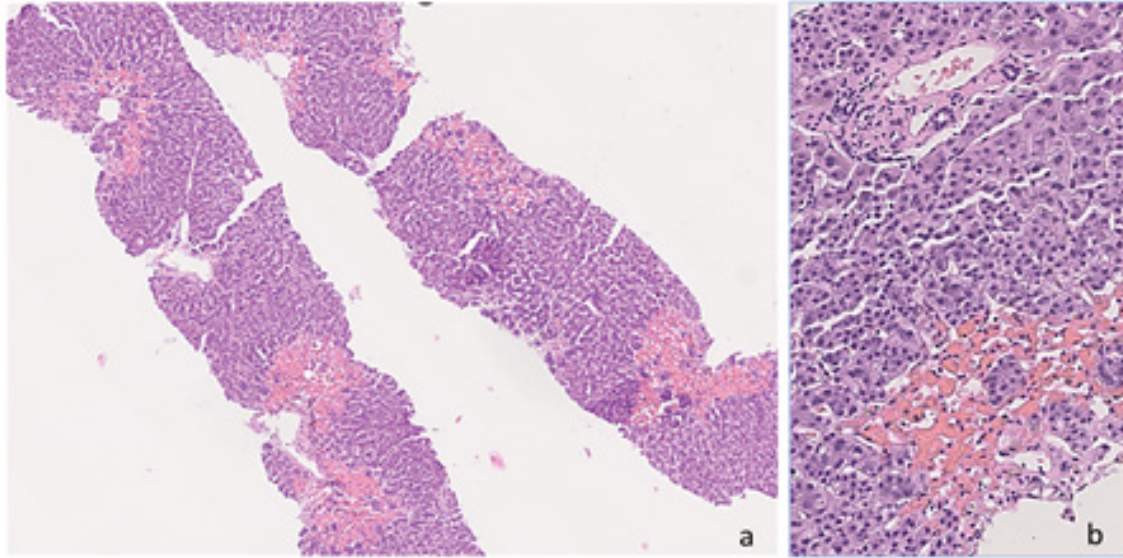
increased, and RRT was interrupted. By day seven serum creatinine improved to 3.76 mg/dl and at the end of the first week of his hospitalization his urine appeared clear and total 24-hour output was 3400 mL.

Further hematochemical and microbiological exams were performed to exclude infectious, metabolic, neoplastic, toxic, and autoimmune diseases. We undertook a full renal screen: Immunoglobulin testing revealed levels of IgA 2.98 g/L (RR 0.70-4.00 g/L), IgG 8.58 g/L (RR 7.0-16. g/L), IgM 0.39 g/L (RR 0.40-2.28 g/L). Serum free light chains were within normal limits. Protein electrophoresis showed increased inflammation proteins. Autoantibody serology testing was negative for LKL, ASMA, ANA, AMA, anti-thyroperoxidase (TPO) and anti-thyroglobulin (TG). Virus serology indicating active infection with Hepatitis A, Hepatitis B, Hepatitis C, Hepatitis E, HIV, Epstein-Barr virus (EBV), cytomegalovirus (CMV), herpes virus-6 (HHV6), herpes virus-8 (HHV8) and adenovirus were all not detected.

Also, PCR for parvovirus B19, enterovirus, parechovirus, hantavirus were all negative. Bacterial serology indicating active infection with *Mycoplasma pneumoniae*, *Chlamydia pneumoniae* and *Coxiella burnetii* were negative, including urine antigens for *Legionella pneumophila* and *Streptococcus pneumoniae* and blood cultures, coproculture, and urine culture performed at admission. We also check for toxic etiology: urine analysis for tricyclic antidepressants, barbiturates and benzodiazepines were negative; blood levels of acetaminophen, copper and ammonium were on range. No alteration with thyroid function was identified.

Abdominal CT scan and renal ultrasound showed mild imbibition of the perirenal leaflets, description compatible with an AKI. On day 5 from admission, a liver biopsy was performed. Liver histology (Figure 1) revealed confluent centrilobular haemorrhagic necrosis without any coexistent inflammatory infiltrate. The liver parenchyma outside the necrotic areas only displayed mild hepatocellular regenerative changes; steatosis, cholestasis and fibrosis were not detected. Portal tracts were within normal limits, with no inflammation and no bile duct or vascular damage. This morphologic picture was not consistent with acetaminophen toxicity, characteristically causing a zonal perivenular necrosis but of coagulative type. Instead, it was much more similar to histopathological features already described in liver biopsies from COVID-19 positive patients [8]. Given the clinical context, and following literature evidence, the morphological finding was suggestive of COVID-related microvascular damage. Considering both the acute clinical course and normal biochemical findings checked 1 year before hospitalization for a simple cosmetic surgery, a chronic etiology of the hepato-renal disease was ruled out.

Liver and kidney function was gradually improving. During all the hospital stay, the patient did not have



**Figure 1:** a) Liver biopsy showing diffuse red blood cell extravasation with hepatocyte necrosis in all centrilobular areas (H&E original magnification X 2.5); b) A representative normal looking portal tract; the surrounding parenchyma is spared by necrosis; only perivenular hepatocytes are involved by haemorrhage (H&E original magnification X 10).

**Table 1:** Complete recovery of liver and kidney function twenty-eight days after the onset of symptoms.

	Day 0	Day 1	Day 5	Day 10	Day 15	Day 25	Day 60
WBC [4.4-11] x10 <sup>9</sup> /L	8.60	6.67	13.19	10.09	6.91	7.61	5.77
Hb [123-153] g/L	111	102	96	94	93	108	124
Platelet count [150-450] x10 <sup>9</sup> /L	164	140	521	787	788	547	429
Blood urea [2.5-7.5] mmol/L	9.90	10.20	8.90	12.80	4.50	2.90	4.70
Serum creatinine [45-84] umol/L	817	828	613	217	108	83	79
Na <sup>+</sup> [136-145] mmol/L	122	123	131	139	139	140	140
K <sup>+</sup> [3.4-4.5] mmol/L	4.0	4.5	3.3	3.1	4.7	3.4	3.5
AST [10-35] U/L	875	547	30	98	59	31	23
ALT [7-35] U/L	1394	1076	192	129	100	37	23
gGT [3-45] U/L	376	334	155	121	103	64	24
Total serum bilirubin [1.7-17] umol/L	11.8	11.7	6.3	9.8	7.4	5.8	6.9
CRP [0.0-5.0] mg/L	3.05	2.91	1.90	2.12	0.81	< 0.60	< 0.60

respiratory symptoms and continued to oxygenate well on room air. SARS-CoV-2 molecular swab became negative in fourteen days and the patient was discharged fifteen days after admission. Follow-up showed complete recovery of liver and kidney function twenty-eight days after the onset of symptoms (Table 1).

## Discussion

In this report, we describe a recent and unique case of acute renal failure and hepatocellular injury occurring in an otherwise healthy woman; she had a complete clinical and laboratory recovery after a short-term hemodialysis and adequate fluid and hemodynamic management with documented clinical stability after 30 days of follow-up.

Even though COVID-19 is most well-known for causing different grade of severity pulmonary diseases, extrapulmonary manifestations of COVID-19 involving hematologic, cardiovascular, renal, gastrointestinal, hepatobiliary, neurologic, and dermatologic systems have been described by many clinicians [1]. The exact pathophysiological mechanism of SARS-CoV-2-induced organ injury is still poorly understood, but some evidence has shown it may be multifactorial. It includes direct virus damage, immunological dysregulation, hypoperfusion, vascular damage related to microthrombosis, secondary infection and exposure to nephro and hepatotoxic drugs [9]. In our case the hystopatology analysis of the liver biopsy demonstrated the presence of haemorrhagic necrosis

confirming a possible direct viral toxicity, endothelial cell damage, thromboinflammation and dysregulation of the immune response. Unfortunately, renal biopsy was not obtained because of patient refusal. However, both the relative fast resolution of the process and the laboratory work-up that excluded other secondary causes of the acute renal failure, likely suggest that SARS-CoV-2 infection may have played a major role in the pathophysiology of kidney involvement.

A systematic review and meta-analysis reported that, compared with patients with non-severe disease, patients with severe COVID-19 had a higher risk of developing gastrointestinal symptoms and liver injury [1]; aminotransferases may be elevated but generally remained less than five times the upper limit of normal, reporting only rarely severe acute hepatitis. Our patient presented isolated gastrointestinal symptoms and acute hepatitis in the absence of respiratory symptoms. The concurrent fever was the only element that prompted to get the SARS-COV-2 test. This case highlights the variability in presentation and severity of SARS-COV-2 infection, a field that may require further attention also in the perspective of new virus variants. In addition, clinicians should be aware that COVID-19 may be considered as a differential diagnosis in patients with gastrointestinal symptoms and liver injury even in absence of respiratory symptoms, prioritizing the SARS-COV-2 testing in the emergency rooms.

In our case, no target SARS-COV-2 antiviral therapy was initiated, and the infection self-resolved in 14 days. It is worth noting that antiviral treatment is not recommended in the presence of severe renal and/or liver impairment. Furthermore, antiviral drugs themselves may cause drug-induced liver injury, often prolonging the length of hospital stay [10]. As patients with underlying hepatic and renal comorbidities are often at risk for worse progression of SARS cov-2 infection, more studies are needed to further evaluate the risks and benefits of antiviral agents in these subgroups of patients.

Finally, the case is also of particular interest because it occurred during a milder pandemic wave in which the globally widespread of Omicron variants and their different sublineages have been associated to generally lower disease severity than other SARS-CoV-2 strains, with the only exception for elderly population and profound immunosuppressed patients

who continue to be negatively impacted by this infection. We cannot exclude more atypical cases to occur in light of the continued circulation of milder SARS-CoV-2. In this context the implementation of multiple strategies including genomic surveillance of the virus at the local level, access to anti-SARS-CoV-2 vaccines, the availability of protection disposals, identifying infected patients, and implementing appropriate containment strategies are key to reducing the spread of new variants of SARS-CoV-2, preventing the emergence of new variants of the virus, and finally being able to reach the end of this pandemic.

## References

1. Gupta A, et al. Extrapulmonary manifestations of COVID-19 Nature Medicine 26 (2020): 1017-1032.
2. DicksonWL, Wong W. Multisystemic Cellular Tropism of SARS-CoV-2 in Autopsies of COVID-19 Patients. Cells 10 (2021): 1900.
3. COVID -19-associated AKI. Curr Opin Crit Carte 28 (2022): 630-637.
4. Volbeda M, Jou-Valencia D, van den Heuvel MC, et al. Acute and chronic histopathological findings in renal biopsies in COVID-19. Clin Exp Med 18 (2022): 1-12.
5. Prognostic factors for mortality, intensive care unit and hospital admission due to SARS-CoV-2: a systematic review and meta-analysis of cohort studies in Europe. Eur Respir Rev 31(2022): 220098.
6. European Journal of Gastroenterology and Hepatology 33 (2021): 309-311.
7. Guan WJ, Ni ZY, Hu Y, et al. Clinical characteristics of coronavirus disease 2019 in China. N Engl J Med 382 (2020): 1708-1720.
8. Fassan, et al .Pathol Res Pract (2021).
9. Wang X, Marfella R, Santulli, G. Hypertension, Thrombosis, Kidney Failure, and Diabetes: Is COVID-19 an Endothelial Disease? A Comprehensive Evaluation of Clinical and Basic Evidence. J. Clin. Med 9 (2020): 1417.
10. Clinical Gastroenterology and Hepatology 18 (2020): 1561-1566.